

Relation of Clinical Features with Microbiological Findings in Children of Suspected Pulmonary Tuberculosis

Anand Kumar Bhardwaj, Gurpreet Singh, Kusum Mahajan, Gauri Chauhan, Charu Chandwani

ABSTRACT

Introduction: Tuberculosis (TB) is an important cause of morbidity and mortality in children especially in TB endemic settings. In endemic regions of TB, it is a major yet an unrecognised factor for death among children. Children are usually assessed when they present with symptoms or signs associated with TB. The standard tuberculin test can be used as an adjunct in diagnosing TB in children, however definitive proof for lesion being of tuberculous origin is finding of tubercle bacilli.

Aim: To determine the association between the clinical features in suspected pulmonary TB with sputum positivity.

Materials and Methods: Mantoux test for every child suspected to be suffering from TB was done. X-ray radiography was done and findings were recorded from December 2017 to June 2019. Two sputum samples were collected from

every suspected case. One in a sterile specimen cup with a tight-fitting cap was sent for Ziehl-Neelsen staining and the other in a falcon tube was sent for Cartridge Based Nucleic Acid Amplification Test (CBNAAT). The data was analysed using Microsoft SPSS version 26.0 and along with graph pad prism software.

Results: Out of 53 subjects, 10 patients (19%) tested positive for acid fast bacilli via Ziehl-Neelsen staining as well as CBNAAT and remaining 43 patients (81%) tested negative. Mantoux test results were not significantly different from the percentage of patients with sputum negativity (93.02%). The percentage of sputum positive patients with cavitations on chest X-ray was 70% which was significantly higher.

Conclusion: Females were more likely to suffer from TB disease as compared to the males. Sputum positivity was significantly associated with cavitory lesion on chest X-ray.

Keywords: Cartridge based nucleic acid amplification test, Tuberculin skin test, X-ray radiography

INTRODUCTION

Pulmonary TB is a very rife disease among third world nations. Globally, TB continues to have an unacceptably high toll of disease prevalence and death among children. The disease burden is especially high among children of the low socio-economic groups who provide virgin fertile soil for the organisms to thrive and multiply [1].

The possibility of TB should always be kept in mind especially in children with a history of contact or those belonging to a high-risk area or ethnic group [2]. The improvements in diagnostic yield, especially in techniques of sputum collection and rapid molecular testing have been encouraging, but still, lack sensitivity for this population [3].

The definitive proof for the lesion being of tubercular in origin is the finding of tubercle bacilli. The demonstration of TB bacilli is dependent upon the adequacy of sputum specimen and upon the number of bacilli per mL in the sputum. The standard

tuberculin skin test recommended for use is the Mantoux test [4]. A positive Tuberculin skin test/Mantoux positive is defined as 10 mm or more induration at 48 to 72 hours [5]. A positive TST (Tuberculin Skin Test), indicating infection with TB, does not necessarily indicate the disease. However, it is a useful tool in diagnosing TB in a child when used with symptoms and other evidence of TB disease.

Culture is the gold standard for definitive diagnosis of TB. Culture of *Mycobacterium tuberculosis* is important as it is much more sensitive than microscopy, being able to detect as few as 10 to 100 bacteria/ml of digested concentrated material [6]. It also aids in precise species identification and drug sensitivity testing. Hence, it has been observed that when clinical symptoms are suggestive of TB, the microbiological confirmation may be lacking. The present study was conducted to find association between the clinical features in children of suspected pulmonary TB with the sputum positivity.

MATERIALS AND METHODS

It was a prospective observational study conducted in the paediatric department at the Maharishi Markandeshwar (deemed to be university), Mullana, Ambala, Haryana, India. The study protocol was conducted after approval from the Institutional Research And Ethics Committee (IEC-1090). All the patients who met the inclusion criteria (53 children) were enrolled in the study after obtaining an informed written consent. Study was conducted for duration of one and half years from December 2017 to June 2019.

Inclusion Criteria

In accordance with the Revised National TB Control Program (RNTCP) guidelines issued in the Technical and Operational Guidelines for TB Control in India 2016 [7], children aged between 6 months to 18 years presenting with constitutional symptoms like persistent fever >2 weeks without a known cause and/or unremitting cough for >2 weeks and/or weight loss of 5% in three months or no weight gain in past three months along with any one of the following findings i.e., history of contact or Mantoux positive. Chest X-ray was done and reported by the radiology department and findings suggestive of TB like hilar and paratracheal lymphadenopathy, parenchymal lesions, cavitory lesions were noted.

Exclusion Criteria

Children who were already on Antitubercular Therapy (ATT) had any unexplained illness; were asthmatic; had possibility of foreign body aspiration leading to non-resolving pneumonia or HIV positive cases.

The children were of either sex of age 6 months to 18 years who fulfilled the inclusion and exclusion criteria. A detailed history was taken and general examination was done to see for lymphadenopathy, cutaneous TB markers, anthropometry, respiratory system findings and organomegaly. Mantoux test was carried out in every child (suspected to be suffering from TB) by injecting 5TU of tuberculin intradermally into the anterior aspect of left forearm. The result was read between 48-72 hours of injection. An induration of less than 5 mm around the injected site was taken as negative and 10 mm or more was taken as positive [4]. On the basis of the history, clinical examination and investigations, a diagnosis of pulmonary TB was made.

Two sputum samples were collected from each patient. One in a sterile specimen cup with a tight-fitting cap was sent for Ziehl-Neelsen (ZN) staining and the other one in a falcon tube to be sent for CBNAAT to TB hospital Ambala and report were collected. CBNAAT is a Polymerase Chain Reaction (PCR) based method which can detect the presence of *Mycobacterium tuberculosis* and provide results within 100 minutes [8].

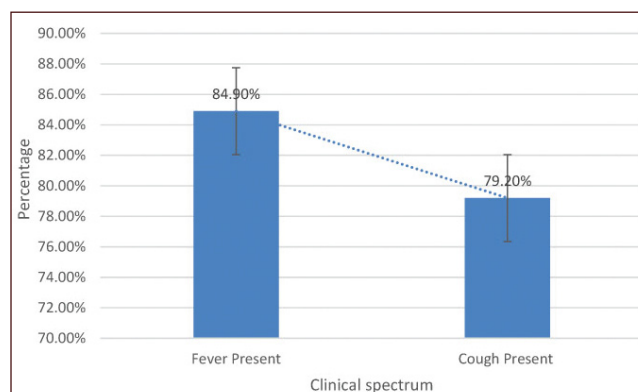
STATISTICAL ANALYSIS

The data recorded from the study was tabulated into a master chart. Results were expressed as number and percentage. The data was analysed using Microsoft SPSS version 26.0 and along with graph pad prism software. Chi-square test was used for comparison between attributes. The p-value <0.05 was considered significant.

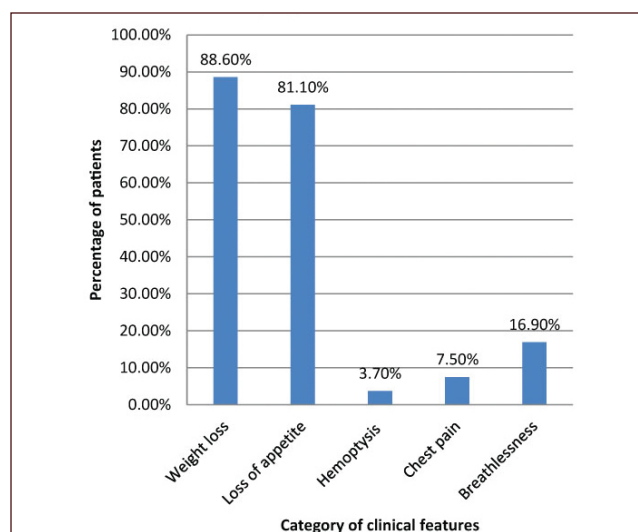
RESULTS

A total of 53 paediatric inpatients with mean age of 10.51 ± 4.855 years were included in the study. The median age was found to be higher (12 years). A total of 60% subjects in the study belonged to more than 10 years of age. There was a female preponderance in the study. Only 22 (41.50%) male patients were present in the study compared to 31 (58.50%) female patients.

Fever was found to be the most common complaint followed by cough [Table/Fig-1]. Associated symptoms experienced by most of the patients consisted of weight loss and loss of appetite at time of presentation. Haemoptysis, chest pain and breathlessness were relatively less prevalent [Table/Fig-2].



[Table/Fig-1]: Clinical features of the overall study population.



[Table/Fig-2]: Associated symptoms of the overall study population.

Out of 53 subjects, 19% of the patients tested positive for *Mycobacterium tuberculosis* and remaining 81% tested negative both by ZN staining and CBNAAT [Table/Fig-3]. The proportion of CBNAAT positive patients with cavitation on chest X-ray were 70% and were significantly higher ($p=0.0017$) [Table/Fig-4].

Sputum Result (ZN staining)	Total Number of patient's n (%)
Positive	10 (18.9%)
Negative	43 (81.1%)
Sputum Result (CBNAAT)	
Positive	10 (18.9%)
Negative	43 (81.1%)

[Table/Fig-3]: Sputum positivity by ZN staining and CBNAAT in overall population.

	Sputum positive patients	Sputum negative patients	p-value
Cavitation present	7	7	0.0017
Cavitation absent	3	36	

[Table/Fig-4]: Comparison between cavitation and sputum positivity.

DISCUSSION

This study was conducted to evaluate the clinico-radiological features in children suspected of pulmonary TB and to compare them with the sputum results. There exists no valid proof that pulmonary TB has any sexual predominance, however in the results obtained in the present study and as described by majority of authors, pulmonary TB was found to be more prevalent among females as compared to males [Table/Fig-5] [9-11].

	Sharma S et al., [9]	Mazta SR et al., [10]	Mahomed H et al., [11]	Present study
Male	38.3%	35%	46%	41.5%
Female	61.7%	65%	54%	58.5%

[Table/Fig-5]: Comparison between various studies for sexual predominance [9-11].

In the present study, 87% of the females were found to be undernourished. Henceforth, it is possible to hypothesise that higher frequency of disease in the females can be attributed to neglect of the girl child in the region leading to poor nutritional status, making them more vulnerable to the disease.

The most common presentations in symptomatic children suspected of pulmonary TB are fever, cough and weight loss. In the present study, fever was the most common presenting symptom followed by cough. The results were similar to as described by majority of the authors showing fever being the most common presentation [Table/Fig-6] [12-14]. Other prominent symptoms, in the beginning of the illness, consisted of weight loss (88%), loss of appetite (81%), and breathlessness (17%).

Early diagnosis and treatment is critical to reduce transmission of TB. Sputum microscopy for AFB using ZN staining is a simple,

	Sreeramareddy CT et al., [12]	Shreshtha S et al., [13]	Panigatti P et al., [14]	Present study
Fever	43%	76%	84%	85%
Cough	23%	63%	46%	79%

[Table/Fig-6]: Presenting complaints across various studies [12-14].

easy and economical test for diagnosing pulmonary TB. CBNAAT has been endorsed by WHO in the recent past for diagnosis of TB as it is not only more sensitive but also tells about the resistance to rifampicin. The present study provided comparison between the sputum results obtained via ZN staining and CBNAAT. In the present study, out of 53 subjects suspected of having pulmonary TB, only 10 subjects (19%) showed positive for the presence AFB by ZN staining as well as CBNAAT. Remaining 43 subjects (81%) tested negative both by ZN staining as well as by CBNAAT. The results obtained in the present study were different from the observations made by other authors. Alvarez-Uria G et al., concluded smear positivity in 69% patients against CBNAAT which showed positivity in 75% patients [15]. In a similar study conducted by Dewan R et al., sputum positivity by ZN staining was seen in 11% patients against CBNAAT which showed sputum positivity in 40% patients [8]. The differences are more likely related to the fact that the adequacy of the sputum samples were not taken into consideration during sample collection. Moreover, the paucibacillary nature of the tuberculous bacilli in the sputum samples giving false negative results, as is clearly evident in the literature [16].

In the present study, it was also observed that sputum positivity was significantly higher among patients with history of contact or exposure. Significant association between history of contact and sputum positivity was seen in studies conducted by Sekadde MP et al., and Arora A et al., respectively [17,18].

Cavitary lesion on chest X-ray is a hallmark finding and marks the presence of progressive primary disease or adult onset TB in children. In the present study, it was found that proportion of sputum positive patients with cavitation was significantly higher ($p=0.0017$). The importance of cavitation in TB is that it provides communication to the bacteria with the environment leading to a oxygenated environment inside the cavitation resulting in bacterial proliferation [19]. Hence children with cavitary lesion in chest X-ray or adult type of TB have a greater chance of having sputum positivity.

Limitation(s)

The sample size used in the study was small. The adequacy of the sputum sample was not taken in to consideration.

CONCLUSION(S)

The present study concluded that females were more likely to suffer from TB disease as compared to the males. The study also found out that the patients with clinical finding suggestive of pulmonary Koch's do not always have sputum CBNAAT

positivity. Sputum positivity was significantly associated with cavitary lesion on chest X-ray.

REFERENCES

- [1] Newton SM, Brent AJ, Anderson S, Whittaker E, Kampmann B. *Lancet Infect Dis.* 2008;8(8):498-510.
- [2] Hoskyns W. Paediatric tuberculosis. *Postgrad Med J.* 2003;79(931):272-78.
- [3] Graham SM, Sismanidis C, Menzies HJ, Marais BJ, Detjen AK, Black RE. Importance of tuberculosis control to address child survival. *Lancet (London, England).* 2014;383(9928):1605-07.
- [4] Seth V, Kabra SK. Conventional Methods. In: *Essentials of tuberculosis in children.* 3rd edition. Jaypee Brothers Medical Publishers (P) Ltd., New Delhi. 2006. Pp. 323-38.
- [5] Howard TP, Solomon DA. Reading the tuberculin skin tests. Who, when, and how? *Am J Infect Control.* 1989;17(5):274.
- [6] Parsons LM, Somoskövi Á, Gutierrez C, Lee E, Paramasivan CN, Abimiku AL, et al. Laboratory diagnosis of tuberculosis in resource-poor Countries: Challenges and opportunities. *Clin Microbiol Rev.* 2011;24(2):314-50.
- [7] Chaudhuri AD. Recent changes in technical and operational guidelines for tuberculosis control programme in India - 2016: A paradigm shift in tuberculosis control. *J Assoc Chest Physicians.* 2017;5(1):1-9.
- [8] Dewan R, Anuradha S, Khanna A, Garg S, Singla S, Ish P, et al. Role of cartridge-based nucleic acid amplification test (CBNAAT) for early diagnosis of pulmonary tuberculosis in HIV. *JIACM.* 2015;16(2):114-17.
- [9] Sharma S, Sarin R, Khalid UK, Singla N, Sharma PP, Behera D. The DOTS strategy for treatment of paediatric pulmonary tuberculosis in South Delhi, India. *Int J Tuberc Lung Dis.* 2008;12(1):74-80.
- [10] Mazta SR, Kumar A, Kumar P. Demographic profile of childhood TB cases under Revised National Tuberculosis Control Program in Himachal. *Natl Tuberc Inst Bull.* 2012;48(1and4):1-9.
- [11] Mahomed H, Ehrlich R, Hawkrigde T, Hatherill M, Geiter L, Kafaar F, et al. TB Incidence in an Adolescent Cohort in South Africa. Ruhwald M, editor. *PLoS One.* 2013;8(3):e59652.
- [12] Sreeramareddy CT, Ramakrishnareddy N, Shah RK, Baniya R, Swain PK. Clinico-epidemiological profile and diagnostic procedures of pediatric tuberculosis in a tertiary care hospital of western Nepal-A case-series analysis. *BMC Pediatr.* 2010;10:57.
- [13] Shrestha S, Bichha RP, Sharma A, Upadhyay S, Rijal P. Clinical profile of tuberculosis in children. *Nepal Med Coll J.* 2011;13(2):119-22.
- [14] Panigatti P, Ratageri VH, Shivanand I, Madhu PK, Shepur TA. Profile and outcome of childhood tuberculosis treated with DOTS-An observational study. *Indian J Pediatr.* 2013;81(1):9-14.
- [15] Alvarez-Uria G, Azcona JM, Midde M, Naik PK, Reddy S, Reddy R, et al. Rapid diagnosis of pulmonary and extrapulmonary tuberculosis in HIV-infected patients. Comparison of LED Fluorescent Microscopy and the GeneXpert MTB/RIF Assay in a District Hospital in India. *Tuberc Res Treat.* 2012;2012:932862.
- [16] Djouhra AM, Ifticene M, Yala D, Boulahbal F. The difficulties of childhood tuberculosis diagnosis. *Int J Mycobacteriology.* 2016;5(5): S10-S11.
- [17] Sekadde MP, Wobudeya E, Joloba ML, Ssengooba W, Kisembo H, Kitaka SB, et al. Evaluation of the Xpert MTB/RIF test for the diagnosis of childhood pulmonary tuberculosis in Uganda: A cross-sectional diagnostic study. *BMC Infect Dis.* 2013;13:133.
- [18] Arora A, Jain AK, Karnawat BS, Kumawat RK. Prospective study to find out the role of gastric aspirate examination by Ziehl-Neelsen staining (ZN staining) and cartridge based nucleic acid amplification test (CB-NAAT) as a diagnostic method in childhood tuberculosis. *Indian J Contemp Pediatr.* 2018;5(4):1609-13.
- [19] Vijayasekaran D, Selvakumar P, Balachandran A, Elizabeth J, Subramanyam L, Somu N. Pulmonary cavitary tuberculosis in children. *Indian Pediatr.* 1994;31(9):1075-78.

AUTHOR(S):

1. Anand Kumar Bhardwaj
2. Gurpreet Singh
3. Kusum Mahajan
4. Gauri Chauhan
5. Charu Chandwani

4. Assistant Professor, Department of Paediatrics, Maharishi Markandeshwar (Deemed to be University), Mullana, Haryana, India.
5. Assistant Professor, Department of Paediatrics, Maharishi Markandeshwar (Deemed to be University), Mullana, Haryana, India.

PARTICULARS OF CONTRIBUTORS:

1. Professor, Department of Paediatrics, Maharishi Markandeshwar (Deemed to be University), Mullana, Haryana, India.
2. PG Resident, Department of Paediatrics, Maharishi Markandeshwar (Deemed to be University), Mullana, Haryana, India.
3. Professor, Department of Paediatrics, Maharishi Markandeshwar (Deemed to be University), Mullana, Haryana, India.

NAME, ADDRESS, E-MAIL ID OF THE CORRESPONDING AUTHOR:

Dr. Gurpreet Singh,
Room No 444, Hostel 9, MMIMSR, Mullana, Haryana, India.
E-mail: dr.gurpreetsingh@yahoo.in

FINANCIAL OR OTHER COMPETING INTERESTS:

None.

Date of Publishing: Jan 01, 2020